



**PATIENT**

Katana Do Couto

**SPECIES**

Canine

**BREED**

Doberman

**SEX**

Female Spayed

**AGE**

3 years

**WEIGHT**

70.5lbs

**INTERPRETED BY**

Maggie Machen Lamy,  
 DVM DACVIM  
 (Cardiology)

**IMAGING PERFORMED BY**

Amanda Stewart

**HOSPITAL NAME**

Southside AC London

**REFERRING VET**

Dr. Lucas

**INVOICE**

46706

**DATE**

2/5/26

**PRESENTING CLINICAL SIGNS**

History: Breed screen exam. No murmur. Asymptomatic. Sedated with Gabapentin

**ECHOCARDIOGRAM FINDINGS**

2D, m-mode, color flow and doppler imaging is available. Normal mitral valve with no obvious prolapse into the left atrial lumen. No mitral regurgitation with a normal left atrial dimension. Normal LV diameter with adequate myocardial function. Normal LV wall thickness. The tricuspid valve is normal with no TR. Normal right atrial and ventricular diameter and morphology indicating no overt evidence of pulmonary arterial hypertension. The pulmonic and aortic valves are normal in morphology and mobility. Normal aortic outflow velocities; laminar flow. Normal pulmonary outflow velocity with trace pulmonic insufficiency. No pericardial or pleural effusion noted.

**CARDIAC CHART**

CANINE CARDIAC PARAMETERS	MR VMAX (m/s)	TR VMAX (m/s)	LA/AO (Boon method)	LA/AO (Heart Base; Swe)	FS (%)	EF (%)	EPSS (cm)
<b>NORMAL PARAMETER</b>	4.5-5.5	<2.7	1.3	<1.6	28-40	40-100	<0.6
<b>PATIENT</b>	NA	NA	NM	1.2	30	58	NM
CANINE CARDIAC PARAMETERS	HR (BPM)	AV VMAX (m/s)	PV MAX (m/s)	BODY WEIGHT (kg)	LA 2D short axis Base view (cm)	LVIDd Avg; 2D and m-mode short axis (cm)	LVIDs Avg; 2D and m-mode short axis (cm)
<b>NORMAL PARAMETER</b>	50-100	0.7-1.7	0.7-1.6	BELOW	BELOW	BELOW	BELOW
<b>PATIENT</b>	NM	1.5	0.8	32.0		3.7	2.6
*Normal chamber parameters expressed as a mean value (SD)				3	1.27	2.46 (2.46)	1.36 (5.5)
<b>BODY WEIGHT DEPENDENT PARAMETERS</b>				5	1.40 (4.5)	2.74 (5.2)	1.60 (4.7)
<i>*Note: All measurements based upon multi-modal images and methods. An average value is reported.</i>				10	1.50 (3.8)	3.27 (3.5)	2.06 (3.1)
				15	1.83 (2.0)	3.71 (2.4)	2.43 (2.1)
				20	2.02 (1.9)	4.14 (2.2)	2.80 (2.0)
				25	2.18 (2.4)	4.48 (2.9)	3.10 (2.5)
				30	2.33 (3.3)	4.83 (3.9)	3.39 (3.4)
				35	2.48 (4.3)	5.17 (5.0)	3.69 (4.5)
				40	2.62 (5.2)	5.48 (6.1)	3.96 (5.4)
				50	2.88 (7.1)	6.07 (8.3)	4.46 (7.4)

**INTERPRETATION OF THE FINDINGS & FURTHER RECOMMENDATIONS**

The cardiac structure and function in this patient are overtly normal, with no evidence of occult DCM or chronic valve disease. The function is reasonable for this signalment, and no significant valvular issues, structural changes or arrhythmias are readily apparent.

In this signalment, recheck echocardiograms are recommended every 6-12 months, particularly given genetic testing. Additionally, holter monitoring every 6-12 months should also be considered to screen for the arrhythmic form of disease. Finally, the BNP test has also been



**PATIENT**

Katana Do Couto

**SPECIES**

Canine

**BREED**

Doberman

**SEX**

Female Spayed

**AGE**

3 years

**WEIGHT**

70.5lbs

**INTERPRETED BY**

Maggie Machen Lamy,  
DVM DACVIM  
(Cardiology)

**IMAGING  
PERFORMED BY**

Amanda Stewart

**HOSPITAL NAME**

Southside AC London

**REFERRING VET**

Dr. Lucas

**INVOICE**

46706

**DATE**

2/5/26

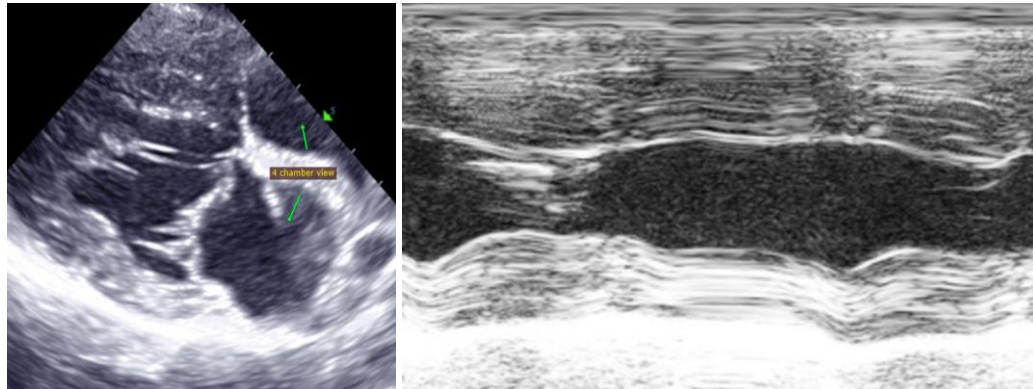
shown to be a decent predictor of occult DCM and can consider routine screening going forward.

No cardiac medications are indicated at this time. Monitor for development of a cough, labored breathing, exercise intolerance or collapse episodes. I generally recommend fish oil supplementation in any Doberman, given the anti-arrhythmic properties of omega fatty acids.

No cardiac contraindication for general anesthesia.

Recheck annually, sooner if clinical signs or a heart murmur develops.

**IMAGES**



**The information and recommendations provided are based on the images presented by the referring veterinarian. No evaluation can be communicated regarding pathology that was not visible in the image/video clips provided.**

Thank you for this referral. This report was generated using transcription software, and minor dictation errors may be present. If the clinical or image interpretation does not parallel your findings or if I can be of any further assistance, please contact me.

**Maggie Machen Lamy, DVM**  
**Diplomate of the American College of Veterinary Internal Medicine (Cardiology)**  
info@sonopath.com